



PATIENT
Spyke Karaskiewicz

PRESENTING CLINICAL SIGNS

History: Spyke is referred to evaluate a heart murmur. Thyroid level normal. She is doing well with a good appetite and activity level. On exam: NSR, grade II/VI parasternal murmur, PSS, lung fields clear, compressible thorax . BP: 100-110mmHg. *No sedation for study.

SPECIES
Feline

ECHOCARDIOGRAM FINDINGS

2D, m-mode, color flow and Doppler imaging is available.

BREED
DSH

Left ventricle: The LV diameter is normal with adequate myocardial function. The LV wall measures normal with the exception of a focal septal thickening. There is a diffusely hyperechoic endocardium consistent with fibrosis. The papillary muscles are mildly remodeled and hyperechoic.

SEX
Female Spayed

Left atrium: The left atrium is normal. No obvious spontaneous contrast or thrombi seen.

Mitral valve: The mitral valve is normal in structure and mobility. No obvious systolic anterior motion is seen. No MR.

AGE
11 years

Aortic valve/Aorta: The aortic valve is normal. Normal aortic outflow velocity; laminar flow. No aortic insufficiency.

Right ventricle: Normal right ventricular diameter and morphology indicating no overt evidence of pulmonary arterial hypertension.

Right atrium: The right atrium is normal in dimension.

WEIGHT
8.9lbs

Tricuspid valve: The tricuspid valve appears normal with trace tricuspid regurgitation.

Pulmonic valve/Pulmonary artery: The pulmonic valve is normal in morphology and mobility. No pulmonic insufficiency. Normal RVOT velocity; laminar flow.

Pericardium/other: No pericardial or pleural effusion noted. No obvious cardiac masses.

INTERPRETED BY

Maggie Machen
Lamy, DVM
DACVIM (Cardiology)

2-Dimensional Measurements

Ao diam (cm)	0.9
LA diam (cm)	1.1
LA:Ao (Swe)	1.2
IVS thickness (cm)	0.63
LVID diastole (cm)	1.55
PW thickness (cm)	0.41
LVID systole (cm)	0.65
FS (%)	58

Doppler Measurements

PV Vmax (m/s)	0.85
AoV Vmax (m/s)	0.97
MR Vmax (m/s)	NA
TR Vmax (m/s)	NA
TR PG (mmHg)	NA

IMAGING PERFORMED BY

Pamela Harrigan,
RDCS

HOSPITAL NAME

Mass Veterinary Services

INTERPRETATION OF THE FINDINGS

The primary abnormality identified is a focal septal thickening. This may reflect early hypertrophic disease or may simply be a normal variant. The remainder of the LV measures normal. No cause for the murmur is identified, making it likely physiologic in origin. Most importantly, the LA measures normal indicating low risk for complication at this time. No additional issues are noted.

REFERRING VET

Dr. Masloski

Prognosis is guarded, due to the highly variable rates of progression with subclinical feline cardiomyopathy.

INVOICE
26868

DATE
10/12/22



PATIENT
Spyke Karaskiewicz

SPECIES
Feline

BREED
DSH

SEX
Female Spayed

AGE
11 years

WEIGHT
8.9lbs

INTERPRETED BY
Maggie Machen
Lamy, DVM
DACVIM (Cardiology)

IMAGING PERFORMED BY
Pamela Harrigan,
RDCS

HOSPITAL NAME
Mass Veterinary
Services

REFERRING VET
Dr. Masloski

INVOICE
26868

DATE
10/12/22

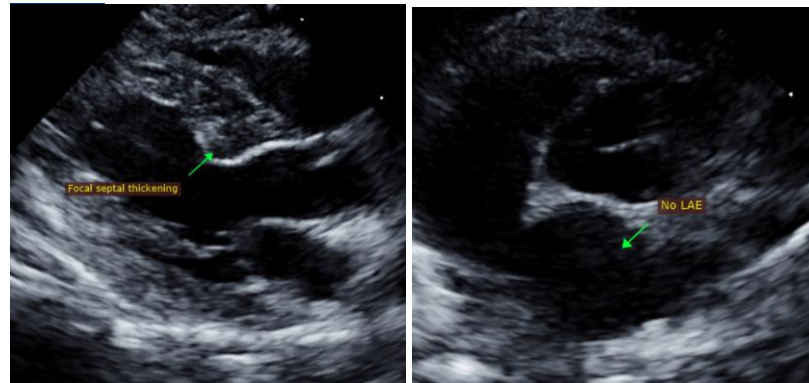
RECOMMENDATIONS

- Given these findings, no medications are indicated.
- Monitor BP and T4 every 6 months.
- Anesthetic risk is considered mild, however judicious IV fluid rates are advised to avoid fluid overload. Additionally, drugs that stimulate heart rate should be avoided unless clinically necessary (glycopyrrolate, atropine). A reasonable protocol includes opioid/benzodiazepine premedication, propofol induction, isoflurane maintenance.
- Risk for complication with steroid use typically follows LA dilation, which in this case is low. That being said, any cat can experience unexpected signs of intolerance and monitoring of RR/RE is advised particularly in the initiation phase.
- Monitor for any clinical evidence of cardiac compromise, including respiratory changes and/or signs of a blood clot event (paralysis, neurologic changes, etc.).

PLAN

- Recommend recheck echocardiogram in 6-12 months to screen for progression, sooner if any clinical signs arise in the interim.

IMAGES



The information and recommendations provided are based on the images presented by the referring veterinarian. No evaluation can be communicated regarding pathology that was not visible in the image/video clips provided.

Thank you for this referral. This report was generated using transcription software, and minor dictation errors may be present. If the clinical or image interpretation does not parallel your findings or if I can be of any further assistance, please contact me.

Maggie Machen Lamy, DVM
Diplomate of the American College of Veterinary Internal Medicine (Cardiology)
info@sonopath.com

Echocardiogram performed by: Pamela Harrigan, RDCS
Pet Animal Ultrasound Service (4paus.com)